

Nugroho

by Jurnal Nasional Ke 2 Rudy

Submission date: 12-Jan-2021 05:34AM (UTC-0400)

Submission ID: 1486235282

File name: 2._Jurnal_Nasional_ke_2.pdf (791.97K)

Word count: 3941

Character count: 21494



1

Subchronic Toxicity Test of Indian Almond (*Terminalia catappa*) Leaves Water Extract on The Liver Histology of Mice (*Mus musculus*)

Rudy Agung Nugroho^{1*}, Ni Cening Sri Puspa¹, Retno Aryani², Widha Prahastika², Rudianto¹, Hetty Manurung³

2

¹ Laboratorium Fisiologi Perkembangan dan Molekuler Hewan, Jurusan Biologi, Fakultas Matematika dan Ilmu Pengetahuan Alam, Universitas Mulawarman, Indonesia 75123

² Laboratorium Anatomi dan Mikroteknik Hewan, Jurusan Biologi, Fakultas Matematika dan Ilmu Pengetahuan Alam, Universitas Mulawarman, Indonesia 75123

³ Laboratorium Fisiologi dan Perkembangan Tumbuhan, Jurusan Biologi, Fakultas Matematika dan Ilmu Pengetahuan Alam, Universitas Mulawarman, Indonesia 75123

* Correspondent email: rudyagung.nugroho@fmipa.unmul.ac.id

ARTICLE INFO

Article history:

Received: 28 Jun 2020

Accepted: 10 Des 2020

Published: 31 Des 2020

Keywords:

Histopathology

Hepar

Indian Almond leaf

Toxicity

ABSTRACT

Background: Indian almond (*Terminalia catappa*) is used as an alternative medicine to treat various diseases. However, limited research has been conducted on the subchronic toxicity of Indian almond water extract on the liver. The present study aimed to determine the subchronic toxic effects of Indian almond leaf water extract on the liver histology of mice and to evaluate the safe dose of Indian almond leaf water extract with various doses (125 mg/kg, 250 mg/kg, 500 mg/kg, 750 mg/kg, and 1000 mg/kg). **Methods:** A total of 33 male mice were randomly divided into 11 groups, each group consisting of three mice as replication. For 30 days, mice in five treatment groups were orally treated every day with water extracts of green Indian almond leaf while other five groups were given water extracts of brown Indian almond leaves and compared with the control group. At the end of day 30, all mice were sacrificed, and the liver was taken out for histological preparations. The histopathological changes in the liver were observed and assessed based on histological damage in degeneration and necrosis. **Results:** The administration of green and brown Indian almond water extract at doses of 125, 250, 500, 750 and 1000 mg/kg BW showed a toxic effect on the liver of mice. The toxic effect was due to the high doses, causing cell swelling damage and increased liver necrosis. **Conclusion:** Indian almond leaf water extract can cause toxic effects on mice's liver at the doses implemented.

Uji Toksisitas Subkronik Ekstrak Air Daun Ketapang (*Terminalia catappa*) terhadap Histologi Hepar Mencit (*Mus musculus*)

ABSTRAK

Background: Tanaman Ketapang (*Terminalia catappa*) sering dimanfaatkan masyarakat sebagai obat alternatif untuk mengobati berbagai penyakit. Namun, belum pernah dilakukan penelitian mengenai toksisitas subkronik ekstrak air tanaman ketapang pada organ hepar. Penelitian ini bertujuan untuk mengetahui efek toksik subkronik ekstrak daun ketapang terhadap histologi hepar mencit dan untuk mengetahui dosis aman ekstrak daun ketapang dengan konsentrasi 125, 250, 500, 750 dan 1000 mg/kg BB. **Metode:** Sebanyak 33 ekor mencit jantan dibagi menjadi 11 kelompok, tiap kelompok terdiri dari tiga ekor mencit. Lima kelompok dengan perlakuan ekstrak air daun ketapang hijau dan lima kelompok dengan menggunakan ekstrak air daun ketapang coklat. Pemberian ekstrak air daun ketapang dilakukan setiap hari selama 30 hari, kemudian dinekrops pada hari ke-30 untuk pembuatan preparat histologi hepar. Perubahan histopatologi hepar diamati dan dinilai berdasarkan kerusakan histologi berupa degenerasi dan nekrosis. **Hasil:** Pemberian ekstrak daun ketapang hijau dan coklat dengan dosis 125 mg/kg, 250 mg/kg, 500 mg/kg, 750 mg/kg, dan 1000 mg/kg BB memberikan efek toksik terhadap hepar mencit. Efek toksik ini disebabkan semakin tinggi dosis, kerusakan pembengkakan sel dan nekrosis hepar meningkat. **Kesimpulan:** Ekstrak air daun ketapang dapat menimbulkan efek toksik pada hepar mencit pada dosis yang dicoba.



Introduction

Indonesia has a variety of medicinal plants, reaching more than 1000 types. The medicinal potential of plants has been introduced from old time ancestors who were then explored scientifically to obtain data scientifically. Several studies have recently been carried out using plants containing secondary metabolites with various molecules and biological activities. One of the plants currently being explored for its potential and use among researchers is Indian almond (*Terminalia catappa*) (Allyn et al., 2018).

Indian almond plant contains allelochemical compounds such as tannins, triterpenoids, flavonoids, alkaloids, steroids, resins and saponins. The previous study revealed that the Indian almond plant was used as a medicinal for fever, itching, and wound healing (Nugroho et al., 2019b; Nugroho et al., 2017; Nugroho et al., 2016; Nugroho et al., 2019c). Toxicity test is a test to evaluate the safety aspects of a drug intended as a medicinal product (Makalalag et al., 2019; Mangirang et al., 2019; Wresdiyati & Handharyani, 2019). While the subchronic toxicity test is a test to evaluate the toxicity of a compound that is performed for a long duration time (Darmawan et al., 2020; Kasmawati et al., 2020). Further, subchronic toxicity test needs to be done on the Indian almond leaves, to evaluate the toxic effects on liver histology.

Previous research stated that *Arcangelisia flava* Merr wood extract at a dose of 250 to 750 mg/kg BW for 28 days did not cause liver damage (Rachmawati & Ulfa, 2018). The similar finding also revealed that the Acutely administration of ethanol extract of Purwoceng (*Pimpinella pruatjan* Molck.) root at various doses (5, 50, 300, and 2000 mg/kg BW) did not cause any damage on the histology of liver (Arjadi et al., 2017). However, a toxic effect was found on the liver of *Rattus norvegicus* after administration of the ethanol extract of mangrove (*Rhizophora apiculata*) stem bark (Ciptaningrum, 2020). The toxic effects of *Cayratia trifolia* L. Domin leaf extract at doses of 5,000 and 50,000 (mg/kg) were also found, causing liver cell damage (Yusuf et al., 2018).

Though several studies have been made to evaluate several plant extract's potential toxicities, no previous research has investigated the subchronic toxicity test of water extract of Indian Almond leaves on the liver histology of Mice (*Mus musculus*). The purpose of the current study was to determine the subchronic toxic effects of water extract of Indian almond either green or brown leaves on the liver histology of mice and to evaluate the safe dosage of water extract of Indian almond both green and brown leaves in a concentration range of 125 to 1000 mg/kg BW. The results of this research are valuable for establishing potential adverse effects of the Indian almond leaves

extract. A further benefit is also useful information for exploring therapeutic and pharmaceutical interest in Indian almond leaves extract to reduce possible adverse effects.

Methods

Research design

Completely randomized design (CRD) was used in this study with three replications. A total of 33 male mice were randomly divided into five treatment groups (green and brown leaves of Indian almond) and one control group with three replications each. Mice in the treatment group were given Indian almond either green or brown water extract; eaves once per day for 30 days with various doses between 125-1000 mg/kg BW.

Extract preparation

Both green and brown (In colour) leaves of Indian almond were obtained from around the Mulawarman University campus, Samarinda. The Indian almond leaves were then cleaned, cut into small pieces about 1 cm. Further, Indian almond leaves were boiled in a ratio of 1 kg of Indian almond leaves to two litres of distilled water at 70 °C for 2 hours. The leaves stew was filtered to separate the water extract from the Indian almond leaves. The water extract was then re-filtered using filter paper and put in a rotary evaporator (Buchi R-210 Rotavapor®), and freeze dryer (Christ Alpha 1-2 LDplus Freeze Dryer) to obtain a crude extract.

Animal preparation and treatment

In total, 33 male mice (2 months old) were purchased from a local breeder, Samarinda. All mice were acclimated for three days. With commercial pellet After acclimatization, the mice were grouped according to treatment and placed in cages. Furthermore, the mice were orally given wither green or brown leaves water extract using a cannula for 30 days. During the treatment, the mice were given commercial pellet feed in an amount of 10% of their body weight and were given drink ad libitum. After 30 days, all mice of each treatment were dislocated, and livers were removed for observation for microscopic histological analysis.

Histology analysis

Each mouse liver was made histologically using the paraffin method and Hematoxylin-Eosin staining. Assessment of liver damage in each of these treatments was carried out by maintaining histological preparations, namely degeneration (cell swelling) and necrosis (cell death). This observation was carried out in five different fields of view on each histological slide. Microscopic

observations were observed from the left, right, top, and followed bottom to the middle of the histological preparation. Histological observations were performed by using light microscopy at a 400X magnification and scoring method.

Data Analysis

The scoring data on the level of change in the histology of the mice's liver was presented in the table and analyzed statistically. The data obtained were as Mean±Standard Error (SE). Data on liver degeneration and necrosis were tested using Kruskal Wallis and Mann Whitney analysis at the significant level of $P<0.05$. Data analysis was performed using SPSS version 22 (SPSS, Inc. USA).

Results

As can be seen from Table 1, the necrosis and degeneration damage of the liver enhances doses. Either green or brown leaves of Indian almond can cause toxic effects on the liver of mice. The present finding indicated that the water extracts of green and brown Indian almond leaves were toxic, leading to degeneration and necrosis.

Table 1. Effect of Water Extract of Indian almond (*Terminalia catappa*) leaves on the necrosis and liver degeneration of mice (*Mus musculus*)

Leaves Types	Doses (mg/kg BW)	Data Scoring	
		Necrosis	Degeneration
Green	Control	0.53±0.05 ^a	0.53±0.02 ^a
	125	1.13±0.08 ^b	1.30±0.05 ^b
	250	1.73±0.08 ^c	2.10±0.05 ^c
	500	2.63±0.03 ^d	2.66±0.08 ^d
	750	2.76±0.03 ^d	3.03±0.03 ^e
Brown	1000	2.83±0.06 ^d	3.23±0.03 ^f
	125	0.66±0.08 ^a	1.00±0.05 ^g
	250	1.23±0.12 ^c	1.23±0.08 ^g
	500	1.80±0.05 ^c	1.83±0.06 ^h
	750	2.13±0.03 ^f	2.10±0.05 ^c
	1000	2.63±0.06 ^d	2.73±0.08 ^d

Note: data are presented as mean±standard error SE). Mean in the same column followed by different superscript letters (a-h) showed significantly different at $P<0.05$. Control (without extract), treatment (mg/kg BW of water extract of green or brown Indian almond leaves)

Meanwhile, histological observations showed that the administration of green and brown Indian almond leaves water extracts caused a change in the histology of the mice's liver along with the increase in dose (Figure 1). There was degeneration of the liver, and accumulation of small white fat, and large vacuoles that push the nucleus to the edge (fat degeneration), swelling of cells, the presence of vacuoles, and hydrophilic degeneration.

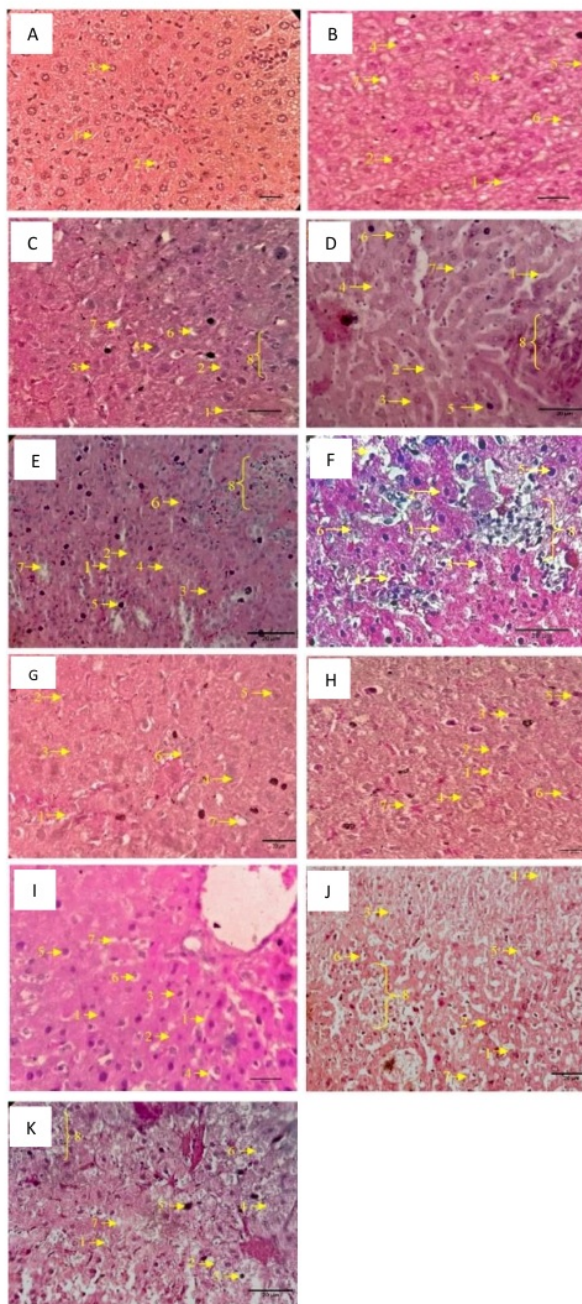


Figure 1. Liver cross-section of mice (*Mus musculus*). Paraffin and Hematoxylin-Eosin Methods, 400x. Description: 1. Sinusoid, 2. Hepatocyte, 3. Hepatocyte nucleus, 4. Degeneration, 5. Pyknosis, 6. Karyorrhexis, 7. karyolysis, 8. Inflammatory cells. (A) liver of the control group, (B-F) green leaves; (G-K) brown leaves, mice group with treatment concentrations were 125, 250, 500, 750 and 1000 mg/ g BW, respectively.

Discussions

The damage was in the form of liver degeneration with green and brown ketapang (Indian Almond) leaf extract treatment, the control and treatment group mice, and significant differences (Table 1). Mice in the treatment group, 1000 mg/kg BW of green leaf ketapang extract, showed that cell damage in the form of liver degeneration was more significant than that of the control group and other treatments. The present finding was similar to the study performed by Wahyuni *et al.* (2017) who stated that the highest dose of the ethyl acetate fraction of the peel of Kandis acid (*Garcinia cowa* Roxb.) was only given once. In contrast, in the present study, the extract was given repeatedly and for a long time, which caused the accumulation of dangerous active ingredients toxic to the test animals.

In the mice treated with brown Indian almond leaves water extract, there was also a significant difference in the degree of liver degeneration among the control group and some of the treatments. The administration of 125 mg/kg BW water extract caused degeneration of the liver, but no significant difference in the liver degeneration in the mice treated with 250 mg/kg BW. According to Lu, (1995), the nature and intensity of a chemical's effect depend on the effective dose. The toxic effects can be reversed if exposed to low levels or for a short time. In mice treated with 125 and 250 mg/kg BW of water extract of both green and brown Indian almond leaves showed the lowest degenerative damage compared to other treatments. In addition, (Lu, 1995) revealed that, if the dose of an active ingredient was increased, the response was also increased, both in terms of the proportion of the population and the severity of the response.

Furthermore, in the mice treated with green Indian almond water extract leaves, there was a significant difference in hepatic necrosis level between the control and treatment groups. Current finding indicated that the dose of 125 mg/kg BW resulted necrosis of the liver. Further, mice treated with 500, 750 and 1000 mg/kg BW Indian almond water extract leaves also had the same ability to destruct the liver cell nucleus (necrosis).

Meanwhile, mice treated with the brown Indian almond water extract leaves above 125 mg/kg BW was found no significant difference in the level of hepatic necrosis compare to the control group and 125 mg/kg BW. Present results indicated that 125 mg/kg BW of brown leaves water extract had the same effect of distilled water (control). However, the mice in the treatment groups of 250, 500, 750 and 1000 mg/kg BW showed a significant difference with the control group. Mice treated above 125 mg/kg BW could damage the cell nuclei in the liver.

In histological observations, the administration of green and brown Indian almond water extracts leaves also caused

degeneration and showed small white fat accumulation, large vacuoles and fat degeneration, cell swelling, empty spaces (vacuoles), and enlarging cells, and hydrophilic degeneration (Figure 1). Previous research results by Fitmawati *et al.* (2018) mentioned that administration of traditional Malay extracts, which contained a mixture of various types of plants, can cause histological liver damage, such as degeneration and necrosis. The increasing dose of both green and brown water extract of Indian almond also enhanced the damage which caused by more chemical compounds entered the mice body, causing heavy metabolism/detoxification of the liver and resulting in cell degeneration. Further cell degeneration caused permanent damage to the cells, resulting from cell necrosis or cell death. Necrosis of cell is indicated by clotting (pycnosis), cracking (cariorexis) and disappearing (karyolysis) of cell (Adinata *et al.*, 2012).

Setyowati, (2010), stated that cell degeneration is reversible but occurs only in the mitochondria and endoplasmic reticulum due to oxidation disorders. Continued degeneration is also characterized by vacuoles with water in it, cytoplasm without fat or glycogen. The cytoplasm shows a pale and swelling due to a fluid accumulation caused by hypoxia and chemical poisoning.

In addition, plant extracts contain chemical compounds such as polyphenols, catechins, and flavonoids which may induce chemical poisoning. Indian almond leaves extract also has tannins and saponins Nugroho *et al.*, (2019a); Nugroho *et al.*, (2019b); Nugroho *et al.*, (2019c) which may potentially cause harmful effects. According to past research performed by Prasetyo *et al.* (2018), tannins are included in polyphenolic compounds, which consist of condensed tannins and hydrolyzed tannins. Condensed tannins are more toxic than hydrolyzed tannins.

In plants, tannins serve as a defence against herbivores (Marsh *et al.*, 2020). Meanwhile, in individuals sensitive to tannins, it may cause kidney, liver, and stomach irritation. Studies in humans stated that high tannins are not recommended for an extended period because it can cause oesophageal cancer (Singh *et al.*, 2019). Besides tannins, Indian almond leaves extract also contains saponins. Saponins can be toxic and cause urticaria (Khan, 2019). Saponin also causes hemolysis of red blood cells. Both tannins and saponins also induce liver cell damage (Chen *et al.*, 2017; Jumain *et al.*, 2018).

Conclusions

The administration of either green or brown Indian almond water extracts leaves for 30 days induced a toxic effect on mice's liver. The higher the dose given, the damage to cell swelling and necrosis of the liver also increases. There is no safe dose with long-term administration of water extract of green or brown Indian almond leaves.

Declaration statement

The authors declare that they have no known competing financial interests or personal relationships that could have influenced the work reported in this paper.

Acknowledgements

The author would like to thank the Biology Department, Faculty of Mathematics and Natural Sciences, Mulawarman University, for all support. Thankful also addressed the animal physiology research team at the Animal Physiology, Development and Molecular Laboratory, to Jemi Martin, Ita Rosita, Desi Ratna Sari and Nurlaila Fitri.

References

- Adinata, M. O., Sudira, I. W., & Berata, I. K. 2012. Efek Ekstrak Daun Ashitaba (*Angelica Keiskei*) Terhadap Gambaran Histopatologi Ginjal Mencit (*Mus musculus*) Jantan. *Buletin Veteriner Udayana*, 4(2), 55-62.
- Allyn, O. Q., Kusumawati, E., & Nugroho, R. A. 2018. Antimicrobial Activity of *Terminalia catappa* Brown Leaf Extracts Against *Staphylococcus aureus* ATCC 25923 and *Pseudomonas aeruginosa* ATCC 27853. *F1000Research*, 7. <https://doi.org/10.12688/f1000research.15998.1>
- Arjadi, F., Kurniawan, D. W., Nugraha, T., Febrin, F. R., Salman, E., & Wyangsari, N. P. 2017. Pengaruh Pemberian Ekstrak Etanol Akar Purwoceng (*Pimpinella Pruatjan* Molk.) Secara Akut Terhadap Fungsi Hepar Tikus Putih (*Rattus Norvegicus*) Jantan: Uji Toksisitas Akut. *PROSIDING*, 7(1).
- Chen, Z., Duan, H., Tong, X., Hsu, P., Han, L., Morris-Natschke, S. L., Yang, S., Liu, W., & Lee, K.-H. 2017. Cytotoxicity, hemolytic toxicity, and mechanism of action of Pulsatilla saponin D and its synthetic derivatives. *Journal of Natural Products*, 81(3), 465-474.
- Ciptaningrum, I. 2020. Uji Toksisitas Subkronis Ekstrak Etanol Kulit Batang *Rhizophora apiculata* Terhadap Histopatologi Hepar Tikus Putih Jantan (*Rattus norvegicus*) Galur Sparague Dawley. *Skripsi, 188250441*(Fakultas Kedokteran, Prodi Pendidikan Dokter).
- Darmawan, E., Narwanti, I., Fatimah, S. F., Wulandari, I. A., Ima, R. P., & Dzulhaifa, D. 2020. The Sub-Chronic Toxicity Test of Meniran (*Phyllanthus niruri* L.) and Pegagan (*Centella asiatica*) Extract In Wistar Strain Rats On Liver And Kidney Function. *Jurnal Farmasi Sains dan Komunitas (Journal of Pharmaceutical Sciences and Community)*, 16(2), 86-95. <https://doi.org/10.24071/jpsc.001674>
- Fitmawati, F., Titrawani, T., & Safitri, W. 2018. Struktur Histologi Hati Tikus Putih (*Rattus norvegicus* Berkenhout 1769) Dengan Pemberian Ramuan Tradisional Masyarakat Melayu Lingga, Kepulauan Riau. *EKOTONIA: Jurnal Penelitian Biologi, Botani, Zoologi dan Mikrobiologi*, 3(1), 11-19.
- Jumain, J., Syahrini, S., & Farid, F. 2018. Uji Toksisitas Akut Dan LD50 Ekstrak Etanol Daun Kirinyuh (*Eupatorium odoratum* Linn) Pada Mencit (*Mus musculus*). *Media Farmasi*, 14(1), 28-34.
- Kasmawati, H., Ihsan, S., Suryani, S., Ruslin, R., & Ruben, S. 2020. Uji Toksisitas Subkronis Sediaan Teh Lansau (*Lansau kita*) Khas Suku Muna Terhadap Mencit Jantan (*Mus musculus*). *Jurnal Sains dan Teknologi Pangan*, 5(2), 2701-2711.
- Khan, N. T. 2019. Therapeutic properties of saponins. *International Invention of Scientific Journal*, 3(01), 409-411.
- Lu, F. C. 1995. Toksikologi dasar. *Asas, organ sasaran dan penilaian resiko. Edisi II. Penerbit Universitas Indonesia. Jakarta*, 428.
- Makalalag, A. K., Sangi, M. S., & Kumaunang, M. G. 2019. Skrining Fitokimia dan Uji Toksisitas Ekstrak Etanol dari Daun Turi (*Sesbania grandiflora* Pers). *CHEMISTRY PROGRESS*, 8(1). <https://doi.org/10.35799/cp.8.1.2015.9442>
- Mangirang, F., Maarisit, W., Mongi, J., Lengkey, Y., & Tulandi, S. 2019. Uji Toksisitas Ekstrak Daun Pare *Momordica charantia* Linn Terhadap Larva *Artemia salina* Leach dengan Metode Brine Shrimp Lethality Test. *Biofarmasetikal Tropis*, 2(1), 22-27.
- Marsh, K. J., Wallis, I. R., Kulheim, C., Clark, R., Nicolle, D., Foley, W. J., & Salminen, J. P. 2020. New approaches to tannin analysis of leaves can be used to explain in vitro biological activities associated with herbivore defence. *New Phytologist*, 225(1), 488-498.
- Nugroho, R. A., Aryani, R., Anggraini, W. D. C., Hardi, E. H., Rudianto, R., Kusumawati, E., Sudrajat, S., Nur, F. M., & Manurung, H. (2019a). Dietary *Terminalia catappa* Leaves Reduced Growth Performance but Increased Hematological Profiles and Survival Rate of *Pangasianodon hypophthalmus*. *IOP Conference Series: Earth and Environmental Science*.
- Nugroho, R. A., Aryani, R., Manurung, H., Rudianto, R., & Prameswari, D. 2019b. Wound Healing Potency of *Terminalia catappa* in Mice (*Mus musculus*). *Eurasia Journal of Biosciences*, 13(1), 2337-2342.
- Nugroho, R. A., Manurung, H., Nur, F. M., & Prahastika, W. 2017. *Terminalia catappa* L. Extract Improves Survival, Hematological Profile and Resistance to *Aeromonas hydrophila* in *Betta* sp. *Archives of Polish Fisheries*, 25(2), 103-115. <https://doi.org/10.1515/aopf-2017-0010>
- Nugroho, R. A., Manurung, H., Saraswati, D., Ladyescha, D., & Nur, F. M. 2016. The Effects of *Terminalia catappa* Leaf Extract on The Haematological Profile of Ornamental Fish *Betta splendens*. *Biosaintifika: Journal of Biology and Biology Education*, 8(2), 241-248. <https://doi.org/10.15294/biosaintifika.v8i2.6519>
- Nugroho, R. A., Utami, D., Aryani, R., Nur, F. M., Sari, Y., & Manurung, H. (2019c). In Vivo Wound Healing Activity of Ethanolic Extract of *Terminalia catappa* L. Leaves In

- 7 Mice (*Mus musculus*). Journal of Physics: Conference Series,
- Prasetyo, Y. E., Made, M., Made, K., & Wayan, S. 2018. Perubahan Histopatologi Hati Mencit yang diberikan Ekstrak Etanol Tanaman Sarang Semut. *Buletin Veteriner Udayana*, 11(1), 44-50.
- Rachmawati, E., & Ulfa, E. U. 2018. Uji Toksisitas Subkronis Ekstrak Kayu Kuning (*Arcangelisia flava* Merr) terhadap Hepar dan Ginjal. *Global Medical & Health Communication*, 6(1), 1-6.
- Setyowati, W. (2010). *Uji Toksisitas Akut Monocrotophos Dosis Bertingkat Per Oral Dilihat dari Gambaran Histopatologi Hepar Mencit Balb/c* Faculty of Medicine.
- Singh, V., Singh, A. P., Sharma, I., Singh, L. C., Sharma, J., Borthakar, B. B., Rai, A. K., Katakai, A. C., Kapur, S., & Saxena, S. 2019. Epigenetic deregulations of Wnt/ β -catenin and transforming growth factor beta-Smad pathways in esophageal cancer: Outcome of DNA methylation. *Journal of cancer research and therapeutics*, 15(1), 192.
- Wahyuni, F. S., Putri, I. N., & Arisanti, D. 2017. Uji Toksisitas Subkronis Fraksi Etil Asetat Kulit Buah Asam Kandis (*Garcinia cowa* Roxb.) terhadap Fungsi Hati dan Ginjal Mencit Putih Betina. *Jurnal Sains Farmasi & Klinis*, 3(2), 202-212.
- Wresdiyati, T., & Handharyani, E. (2019). *Uji Toksisitas Akut Ekstrak Daun Undis (Cajanus cajan) yang Diukur dengan Penentuan LD50 pada Tikus Putih (Rattus norvegicus)* IPB]. Bogor.
- Yus 6 M. I., Wulaisfan, R., Haswika, H., & Wahyuni, W. 2018. Uji Toksisitas Akut dan Gambaran Histopatologi Hepar Mencit yang Diberi Ekstrak Terpurifikasi Daun Galing (*Cayratia trifolia* L. Domin). *Pharmauho: Jurnal Farmasi, Sains, dan Kesehatan*, 4(1).

Nugroho

ORIGINALITY REPORT

8%

SIMILARITY INDEX

7%

INTERNET SOURCES

6%

PUBLICATIONS

2%

STUDENT PAPERS

PRIMARY SOURCES

1	journal.uhamka.ac.id Internet Source	2%
2	ejournal.undip.ac.id Internet Source	1%
3	e-journal.usd.ac.id Internet Source	1%
4	Submitted to University of Oxford Student Paper	1%
5	cybertesis.unmsm.edu.pe Internet Source	1%
6	digilib.unila.ac.id Internet Source	1%
7	journal.unnes.ac.id Internet Source	1%
8	Annik Megawati, Ema Dwi Hastuti, Dessy Erlyani Mugita Sari. "Uji Ketoksikan Akut Buah Parijoto Segar (Medinilla Speciosa) terhadap Mencit Jantan Galur Swiss", Cendekia Journal	1%

of Pharmacy, 2017

Publication

Exclude quotes Off

Exclude bibliography On

Exclude matches < 1%